

TRANSCRANIAL MAGNETIC STIMULATION FOR PREP2 PREDICTION TOOL

Glossary:

EMG	Electromyography
ECR	Extensor Carpi Radialis
FDI	First Dorsal Interosseous
MEP	Motor Evoked Potential
MSO	Maximum Stimulator Output
TMS	Transcranial Magnetic Stimulation

Whether you are new to TMS, or highly experienced, the way you approach the test has a large influence on the patient's experience. If you express feelings of uncertainty or concern about the test, then they will too. Remember that TMS is a safe, painless technique that is well-tolerated, even by people at the acute stage of stroke. Being confident and calm will make TMS a straightforward test for everyone involved.

Patients whose SAFE score is less than 5 on day 3 need TMS to test the function of their descending motor pathways.

- Patients with a SAFE score as high as 4 can be MEP-
- Patients with a SAFE score as low as 0 can be MEP+
- Therefore, the SAFE score alone does not distinguish between MEP+ and MEP- patients, and TMS is required.

1. Screen the patient for contraindications and considerations for TMS.

- a. This can be achieved using the provided TMS Safety Checklist, or an equivalent checklist already in local use.
- b. The patient's physician should be responsible for reviewing the patient's checklist and deciding whether to approve the use of TMS with their patient.

2. TMS can be carried out between 3 and 7 days post-stroke.

- a. This is the time window used in the studies that have developed and validated the PREP2 prediction tool. Testing performed outside these time-frames may affect the accuracy of predictions.
- b. While a patient who is MEP- at this time post-stroke may recover MEPs at a later time, this does not change their predicted upper limb outcome.
- c. If testing is delayed until day 8 – 10, you can only be confident to provide a prediction if the patient is MEP-.
- d. TMS testing performed after 10 days post-stroke is too late.

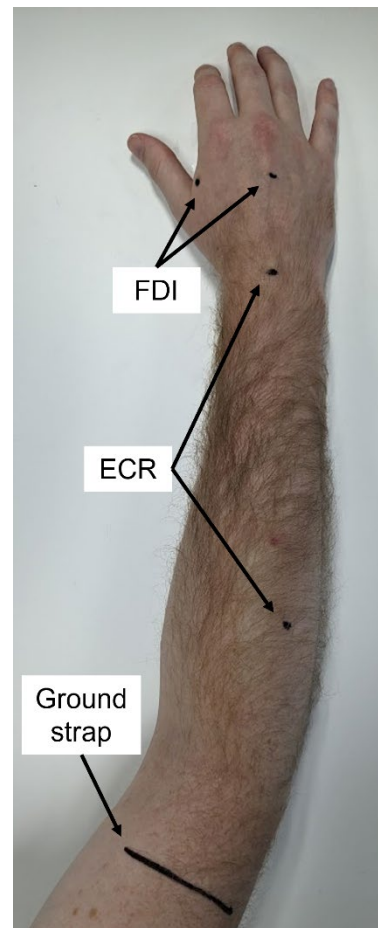
3. TMS can be carried out in the patient's bed space, in a procedure room, or similar location.

- a. The patient can remain in bed in a supine or semi-reclined
- b. The patient can be seated in a chair or wheelchair
- c. The patient should be relaxed and comfortable, with their arms supported on pillows and hands resting with semi-flexed digits

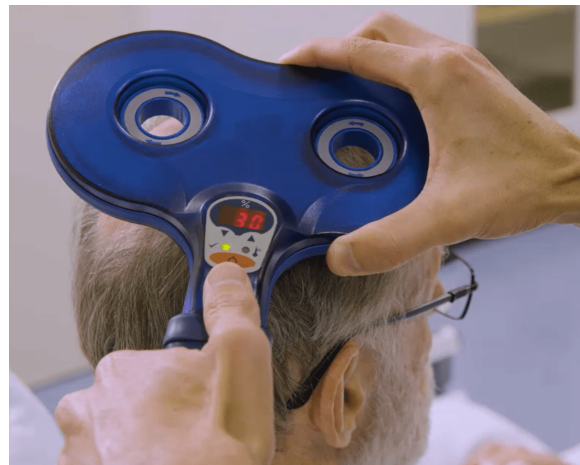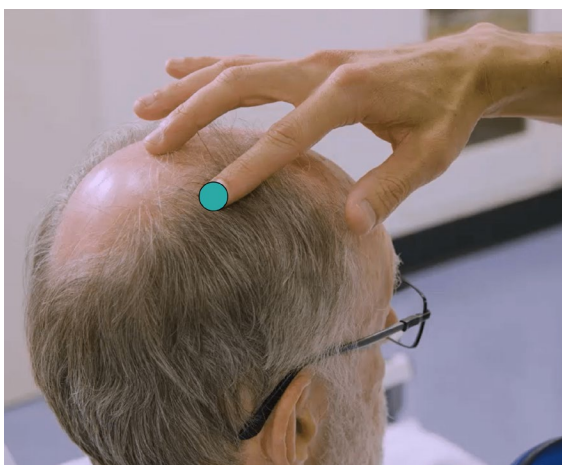4. Explain to the patient that this test will see how well a message can get through from the stroke side of the brain to their weak hand and arm.
 - a. Explain that TMS is painless and non-invasive, and that their doctor has checked that it is safe for them to have this test.
 - b. Explain that you will hold a plastic-covered device gently against their scalp, and it will create a very brief magnetic field that can activate the area of the brain that controls their hand and arm.
 - c. Explain that the device makes a click sound, and they are likely to feel a light tap on their scalp each time it creates the brief magnetic field, but that it won't be uncomfortable.
 - d. Explain that you will start at a low level of stimulation, and gradually increase it, while moving the device around to find the best position for sending a message to their hand and arm.
 - e. Explain that the device can activate the area of the brain that controls their hand and arm, and send a signal down through their nerves that can then briefly activate their muscles; they may feel this as a brief twitch in their muscles, which won't cause any discomfort.
 - f. Explain that you will stick some sensors to the skin on their hand and arm, to detect the activity once it arrives at their muscles.
 - g. Explain that they can let you know if they have any concerns or feel uncomfortable at any stage, and the test can be stopped at any time.

5. Use surface electromyography (EMG) to record from the paretic extensor carpi radialis (ECR) muscles and first dorsal interosseus (FDI).

- a. The belly of each muscle can be located by palpation; it may help to ask the patient to try squeezing their paretic hand.
- b. The ECR electrodes are positioned in a belly-tendon montage, with one over the muscle belly and the other over the dorsal surface of the wrist, 1cm proximal to, and centred between, the radial and ulnar styloid processes.
- c. The FDI electrodes are positioned in a belly-tendon montage, with one over the muscle belly and the other over the dorsal surface of the hand.
- d. A reference electrode is positioned over a bony area, such as the dorsum of the hand or lateral epicondyle of the humerus.
- e. If a ground strap is used instead of a ground electrode then it should be placed around the distal end of the humerus just proximal to the elbow joint, and be snug but not tight.



- f. Use either self-adhesive disposable recording electrodes, or re-usable metal cup electrodes filled with conductive gel or paste and securely taped to each site.
 - g. The skin overlying each electrode site needs to be prepared by shaving to remove any hair, cleaning with an alcohol wipe, and light abrasion with either prep cream or prep tape.
 - h. Take particular care when preparing patients with fragile skin, and avoid any areas of broken skin.
 - i. Once the electrodes are applied, ensure that the signal is free from biological or electrical noise, so that motor evoked potentials (MEPs) can be readily detected.
 - j. If the patient is finding it difficult to relax the recorded muscles, it can be helpful to ask them to relax and drop their shoulders, as well as assisting them to reposition their hand and arm to find a posture that enables muscle relaxation.
 - k. The signal can be sampled at 2 kHz and filtered with a 10 Hz high-pass and 1000 Hz low-pass filters.
 - l. The EMG equipment needs to be triggered by the TMS unit, such that the EMG trace is at least 50 ms in duration prior to each magnetic stimulus, and another 50 ms in duration following each magnetic stimulus.
6. Demonstrate TMS to the patient.
- a. Show the patient the TMS coil and discharge it while holding it away from them, so they can hear the click.
 - b. Position the TMS coil over the stroke affected hemisphere, so they can feel what it is like.
 - c. Let the patient know you will give them one 'click' as a 'tester', then deliver one stimulus at 30% maximum stimulator intensity (MSI), then check with the patient that they are comfortable to proceed with the rest of the test.
7. Position the focal point of stimulation over the stroke affected hemisphere, approximately 4 cm lateral to the vertex.
- a. Ensure the coil is oriented to produce a posterior-to-anterior current flow in the underlying cortex. For a figure-of-eight coil this means having the handle pointing backwards, and at an approximately 45° angle to the mid-sagittal plane.



8. Begin with the stimulus intensity at 30% MSO, and increase it in 10% MSO steps, delivering approximately 3 – 5 stimuli at each intensity and scalp location.
 - a. Move the coil in approximately 1 cm steps (anterior, posterior, medial, lateral) in order to find the optimal location for producing MEPs in the recorded muscles.
 - b. Continue increasing the stimulus intensity and moving the coil until MEPs are consistently observed in one or both muscles, or 100% MSO is reached.
 - c. If 100% MSO is reached, with no MEPs observed, ask the patient to hug a pillow to their chest, using both upper limbs, attempting to activate the muscles of their paretic upper limb to the greatest possible extent.
 - d. Very rarely, patients find higher intensities uncomfortable and ask to take a break or stop before you have observed any MEPs. In this situation, ask the patient to hug a pillow to their chest, and deliver stimuli at the highest tolerable intensity.
 - e. The patient is classified as MEP+ if a MEP is observed with an appropriate latency in response to at least 1 stimulus, with ECR latency \approx 15 – 25 ms, and FDI latency \approx 20 – 30 ms.
 - f. You don't need to observe more than 5 MEPs at a consistent latency in either muscle to be confident the patient is MEP+.
 - g. If you get the sense the patient is uncomfortable and may ask to stop the TMS session prematurely, you can skip remaining intensities and move straight to 100% MSO with active bilateral facilitation to maximise the chances of eliciting an MEP.

9. Interpretation. The patient is classified as
 - a. MEP+: if MEPs are observed with FDI latency \approx 20 – 30 ms, and ECR latency \approx 15 – 25 ms.
 - b. MEP+ patients can be given a prediction of **good** recovery within the next 3 months.
 - c. MEP-: if MEPs are not observed with at rest or during bilateral facilitation at 100% MSO while systematically moving the TMS coil.
 - d. MEP- patients can be given a prediction of **limited** or **poor** recovery depending on their day 3 NIHSS score.

10. Once the test is complete, remove the recording electrodes and clean the underlying skin with an alcohol wipe.
 - a. 'Remove' wipes (Smith and Nephew) can be used to gently remove adhesive tape and electrodes from patients with fragile skin.
 - b. Any reddening of skin prepared for EMG will resolve and does not usually require treatment.